

PATIENT

Mira Schwartz

SPECIES

Feline

BREED

DSH

SEX

FS

AGE

10 y

WEIGHT

9 lb

PRESENTING CLINICAL SIGNS

Grade 3/6 murmur. Previously diagnosed with intermittent SAM in August 2025. Recently diagnosed with hyperthyroidism.

ECHOCARDIOGRAPHIC FINDINGS

2D, M-mode, and Doppler study.

Left atrial size is normal. The mitral valve is normal. Left ventricular wall thickness is normal. Left ventricular internal dimensions are normal. Left ventricular systolic function is hyperdynamic. The aorta and aortic valve are normal. Right atrial and right ventricular dimensions are normal. The tricuspid valve is normal. The pulmonary artery and pulmonic valve are normal. No shunting lesions are visualized. No pericardial effusion or cardiac masses are seen.

LA/Ao - 1.47
 IVSd - 4.3 mm
 LVPWd - 4.3 mm
 LVIDd - 16.2 mm
 LVIDs - 6.6 mm
 FS - 59.3%
 LVOT - 1.31 m/s
 RVOT - 1.07 m/s

ASSESSMENT/RECOMMENDATIONS

This examination demonstrates no abnormalities, though the continued presence of intermittent systolic anterior motion (SAM) of Mira's mitral valve leaflets cannot be ruled out. If intermittent SAM is present, it would likely be the cause of Mira's murmur, however, if it is not, her hyperthyroidism could be the cause, as could another reason for a functional/innocent murmur to develop.

No change in therapy is recommended at this time.

A recheck echocardiogram is recommended in 9-12 months if Mira's murmur persists.

INTERPRETED BY

Keith Blass, DVM, MS,
 DACVIM (Cardiology)

IMAGING PERFORMED BY

Rebecca Hamilton

HOSPITAL NAME

The Venturing Vet

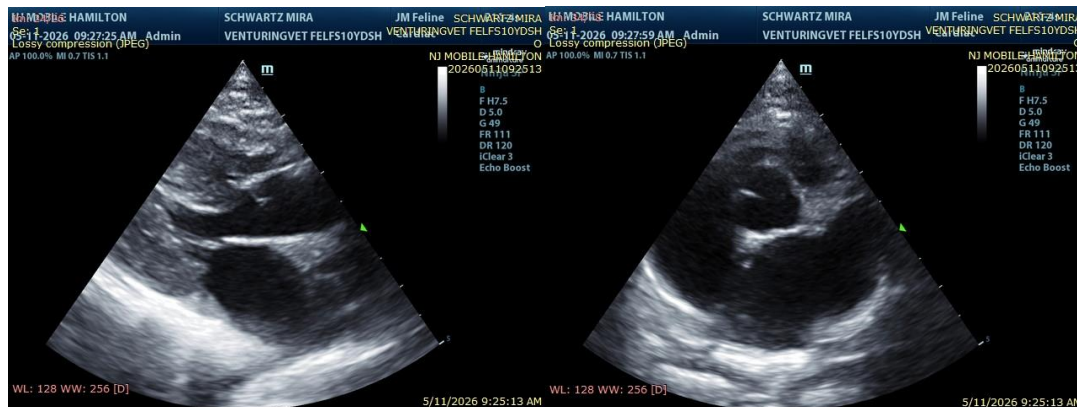
REFERRING VET

Dr. Herzog

INVOICE

DATE

5/11/26





PATIENT

Mira Schwartz

The information and recommendations provided are based on the images presented by the referring veterinarian/sonographer. No evaluation can be communicated regarding pathology that was not visible in the image/video clips provided.

SPECIES

Feline

Thank you for this referral. If the clinical or image interpretation does not parallel your findings or if I can be of any further assistance please contact me.

BREED

DSH

Keith Blass, DVM, MS, DACVIM (Cardiology) info@SonoPath.com

SEX

FS

AGE

10 y

WEIGHT

9 lb

INTERPRETED BY

Keith Blass, DVM, MS,
DACVIM (Cardiology)

IMAGING PERFORMED BY

Rebecca Hamilton

HOSPITAL NAME

The Venturing Vet

REFERRING VET

Dr. Herzog

INVOICE

DATE

5/11/26